



Contents lists available at ScienceDirect

## International Journal of Surgery Case Reports

journal homepage: [www.casereports.com](http://www.casereports.com)

## Living donor liver transplantation with replacement of vena cava for *Echinococcus alveolaris*: A case report<sup>☆</sup>



Ruslan Mamedov<sup>a,b</sup>, Namig Novruzov<sup>a,c</sup>, Adil Baskiran<sup>a</sup>, Fahri Yetisir<sup>d,a,\*</sup>, Bulent Unal<sup>a</sup>, Cemalettin Aydin<sup>a</sup>, Nuru Bayramov<sup>b</sup>, Cuneyt Kayaalp<sup>a</sup>, Sezai Yilmaz<sup>a</sup>

<sup>a</sup> Inonu University, Liver Transplantation Institute, Malatya, Turkey

<sup>b</sup> Azerbaijan Medical University, Baku, Azerbaijan

<sup>c</sup> Central Customs Hospital, Baku, Azerbaijan

<sup>d</sup> Department of General Surgery, Atatürk Research and Training Hospital, Ankara, Turkey

## ARTICLE INFO

## Article history:

Received 9 July 2013

Received in revised form

23 November 2013

Accepted 5 January 2014

Available online 11 January 2014

## Keywords:

Living donor liver transplantation

*Echinococcus alveolaris*

Inferior vena cava

## ABSTRACT

**INTRODUCTION:** There is no medical treatment for alveolar echinococcal disease (AED) of liver till now. Curative surgical resection is optimal treatment but in most advanced cases curative resection can't be done. Liver transplantation is accepted treatment option for advanced AED. AED in some case invade surrounding tissue especially inferior vena cava (IVC). Advanced AED with invasion to IVC can be treated with deceased liver transplantation. Although living donor liver transplantation is very difficult to perform in patients with advanced AED with resected IVC, it come into consideration, since there is very few cadaveric liver.

**PRESENTATION OF CASE:** Here we present a case with advanced stage of AED of liver which cause portal hypertension and cholestasis. AED invaded surrounding tissue, right diaphragm, both lobes of liver and retrohepatic part of IVC. Invasion of IVC forced us to make resection of IVC and reconstruction with cryopreserved venous graft to reestablish blood flow. After that a living donor liver transplantation was done.

**DISCUSSION:** Curative surgery is the first-choice option in all operable patients with AED of liver. Advanced stage of AED like chronic jaundice, liver abscess, sepsis, repeated attacks of cholangitis, portal hypertension, and Budd-Chiari syndrome may be an indication for liver transplantation. In some advanced stage AED during transplantation replacement of retrohepatic part of IVC could be done with artificial vascular graft, cadaveric aortic and caval vein graft.

**CONCLUSION:** Although living donor liver transplantation with replacement of IVC is a very difficult operation, it should be considered in the management of advanced AED of liver with IVC invasion because of the rarity of deceased liver.

© 2014 The Authors. Published by Elsevier Ltd on behalf of Surgical Associates Ltd. All rights reserved.

### 1. Introduction

Hepatic AED results from infection by the larval forms of *Echinococcus multilocularis*. The echinococce almetacestode develops in the liver and is characterized by an alveolar structure, made up by several vesicles surrounded by large granulomas, which grows primarily in the liver of an infected person and develops as a cancer like lesion with slow growth.<sup>1–5</sup> Partial curative surgical resection in early stage and liver transplantation

in advanced stage are accepted treatment options for AED. Many cases of AED are diagnosed at an advanced stage, hence curative partial liver resection can be performed in only 35% of patients<sup>4</sup>. Liver transplantation should be accepted as a life-saving treatment option in patients with AED for whom there is no other medical or surgical treatment option<sup>1</sup>. It is commonly known that AED is characterized by strong adhesions and invasions to the adjacent structures. It complicates the operative technique and increases morbidity and sometimes may increase mortality.<sup>6</sup> The only treatment option for advanced stage of AED with invasion to IVC is liver transplantation with replacement of IVC.

Here we present a patient, who underwent the living donor liver transplantation for hepatic AED with portal hypertension and chronic cholestasis. Strong adhesions to surrounding tissue, right diaphragm and invasion to the IVC forced us to perform resection liver with retrohepatic IVC and reconstruction of resected part of IVC with cryopreserved venous graeff.

<sup>☆</sup> This is an open-access article distributed under the terms of the Creative Commons Attribution-NonCommercial-No Derivative Works License, which permits non-commercial use, distribution, and reproduction in any medium, provided the original author and source are credited.

\* Corresponding author. Atatürk Research and Training Hospital/General Surgery/Ankara/TURKEY Tel.: +90 536 297 48 88.

E-mail address: [drfahriyetisir@hotmail.com](mailto:drfahriyetisir@hotmail.com) (F. Yetisir).

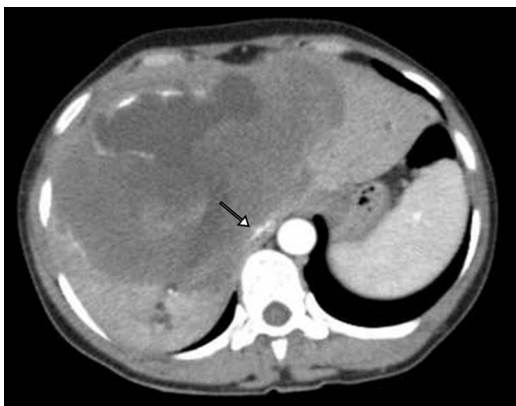

Fig. 1. CT view of liver. Compressed IVC is seen with arrow.

2. Case report

A 49 year old woman with abdominal ascites and edema of lower extremities due to advanced stage AED was transferred to our center. Levels of aspartate aminotransferase: 41 U/L, alanine aminotransferase: 38 U/L, alkaline phosphatase: 688 U/L, gamma-glutamyl transpeptidase: 246 U/L, Total bilirubine: 0,88 mg/dl, direct bilirubine: 0,56 mg/dl, albumin: 2,3 g/dl, BUN: 32 mg/dl and creatinine: 1,59 mg/dl. International Normalized Ratio:1.9 and the model for end stage liver disease score was 11.2. At CT scan it was found a cystic lesion 17.3 × 12 × 15 cm in size without any contrast collecting during all phases, heterogenic and lobulated with calcification on one wall which fills liver segments V-VIII, and partially extending to segment II and III, (Fig. 1). Indirect echinococcal hemagglutination Bhemagglutination test was positive. Because of intrahepatic dissemination of the lesions and IVC compression was chosen as the method of definitive treatment. Mercedes incision

was chosen for abdominal exploration. Large liver with alveolar disease and strong widespread adhesions with surrounding tissues, anterior abdominal wall, right hemidiaphragm and invasion to the retrohepatic part of IVC made recipient hepatectomy more difficult than other cirrhotic livers. Especially invasion to the IVC forces us to perform IVC resection with liver (Fig. 2a), and replacement of resected part of IVC with cryopreserved caval graft (Fig. 2b,c). We did not use veno-venous bypass during IVC reconstruction. A right lobe living related liver transplantation was done. The donor was her nephew. Graft/recipient weight ratios was more than 1% (680 gr/ 66 kg). Venous and arterial reconstructions were carried out with a standard method that was mentioned before.<sup>6</sup> Thus, we used cryopreserved vein grafts surrounding the hepatic veins for extension with 6.0 polypropylene sutures and to make all-in-one orifice. This provided us an easier and large anastomosis with replaced IVC. Portal vein patch or extension is not required for end-to-end porto-portal anastomosis. Portal vein anastomosis was made with 6.0 polypropylene sutures. Arterial anastomosis was performed with x6.5 surgical loupes by separated 8.0 polypropylene sutures. Duct-to-duct biliary anastomosis was performed, an external drainage tube was placed from cystic ductus of recipient in to anastomosis.(Fig. 2d). After 10 months follow up period, routine check-ups of the recipient and the donor were performed. Both of them didn't have any problem.

3. Discussion

Surgery is the first-choice option in all operable patients with AED of liver. Radical resection of the entire hepatic parasitic lesions is the only curative procedure, even though it is often difficult to achieve because of echinococcal dissemination into host tissues. Palliative liver surgery is not an ideal option, because it does not eliminate the disease and makes the secondary treatments more and more challenging.<sup>7</sup> Moreover, its own morbidity and mor-

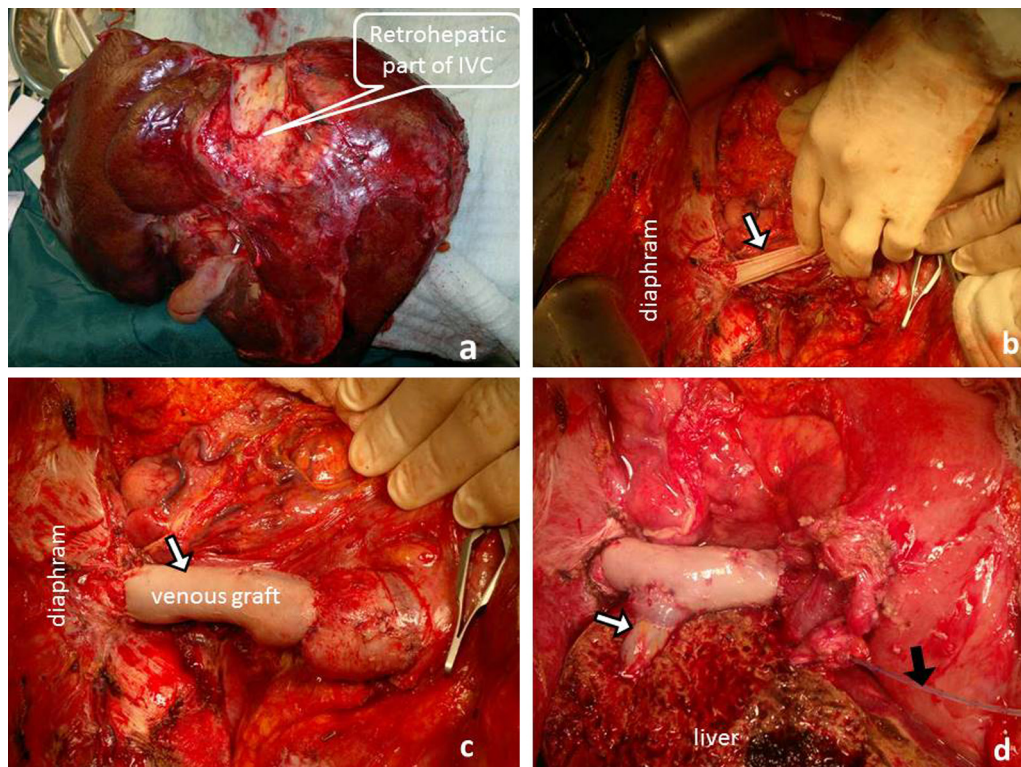


Fig. 2. a. Removed liver with resected part of retrohepatic part of IVC. b. Resection of IVC and replacement with cryopreserved graft. c. Total replacement of retrohepatic part of IVC is seen. d. Final view is seen after reconstruction. External drainage tube is seen with black arrow.

tality is not lower than expected.<sup>5,8</sup> Buttenschoen et al. (2009) reported that palliative surgery was done in 58% of cases and curative resection only in 42%. In the palliative surgery group, morbidity was 19% and 28% died from AED 164–338 months after the first diagnosis (late lethality). The reasons for performing palliative surgery was sometimes the widespread location of the lesions in the liver but sometimes the reason may be the invasions of the major vascularities such as IVC.<sup>8</sup> Clinical findings and complications of multiple AED like chronic jaundice, liver abscess, sepsis, repeated attacks of cholangitis, portal hypertension, and Budd-Chiari syndrome may be an indication for liver transplantation.<sup>9,10</sup> In our case AED invaded all parts of the liver and IVC. Large mass of AED compressing the portal vein and IVC caused portal hypertension and edema of low extremities, respectively. It was decided to be treated with liver transplantation. In 1994 Moreno et al reported five cases of OLT for AED. Two of them had secondary sclerosing cholangitis, two patient had biliary sclerosis and one patient had post necrotic liver cirrhosis.<sup>3</sup> Xia et al. (2005) also reported five cases orthotopic liver transplantation for AED.<sup>11</sup> Resection and reconstruction of IVC during for AED was reported by Moray et al. They reported two cases of liver transplantation for AED and one of them had operation with resection and replacement of IVC with polytetrafluoroethylene graft<sup>1</sup>. In our other experience, we also performed replacement of the IVC for living donor liver transplantation in Budd-Chiari syndrome associated with previous hydatid cyst (cystic echinococcosis) surgery. Retrohepatic part of IVC was replaced with a cadaveric aortic graft.<sup>6</sup> Matsuda H et al. (2010) presented two cases of hepatocellular carcinoma beyond the Milan criteria and they were underwent living-donor liver transplantation combined with aggressive hepatic IVC resection and replacement of the hepatic IVC by an artificial vascular graft. This procedure could be feasible and could prevent post-transplant recurrence in hepatocellular carcinoma beyond the Milan criteria.<sup>12</sup> Recently the resection and reconstruction of IVC during living donor liver transplantation was reported by Ueda J et al (2013). They report on a rare case of surgical resection of an IVC leiomyosarcoma mimicking a hepatic tumor.<sup>13</sup> Most patient series including liver transplantation for AED are related with deceased donors. Koch et al. studied 45 patients at 16 transplant centers in Europe. According to their report, overall 5-year survival and disease-free rates were 71% and 58%, respectively.<sup>10</sup> The authors showed that the most important factor for recurrence and for choosing a treatment option was disease stage. In our case, the liver, the surrounding tissues and the IVC removed completely and IVC was replaced with a cryopreserved cadaveric caval vein graft.

#### 4. Conclusion

Although, living donor liver transplantation with IVC replacement for AED with invasion to the IVC is very difficult operation, it is life - saving option for the patients with advanced stage AED.

#### Conflict of interest Statement

None

#### Funding

None

#### Ethical approval

We have obtained signed consent to publish the case report from the patient

#### Authors' contributions

Ruslan Mamedov and Fahri Yetisir contributed to writing the manuscript; Namig Novruzov, Cemalettin Aydın, Nuru Bayramov and Cuneyt Kayaalp contributed to study design; Adil Baskiran contributed to data collection; Bulent Unal M.D. correct the English; Sezai Yilmaz correct the paper.

#### References

- Moray G, Shahbazov R, Sevmis S, Karakayali H, Torgay A, Arslan G, et al. Liver transplantation in management of alveolar echinococcosis: two case reports. *Transplant Proc* 2009 Sep; **41**(7):2936–8.
- Chomicz L, Szubert A, Fiedor P, Stefaniak J, Myjak P, Zbrowska J, et al. Human cystic and alveolar echinococcoses as indication to liver transplantation. *Transplant Proc* 2003 Sep; **35**(6):2260–1.
- Moreno-González E, LoinazSegurola C, GarcíaUreña MA, GarcíaGarcía I, GómezSanz R, JiménezRomero C, et al. Liver transplantation for Echinococcusgranulosus hydatid disease. *Transplantation* 1994 Oct 15; **58**(7):797–800.
- Bresson-Hadni S, Koch S, Miguet JP, Gillet M, Manton GA, Heyd B, et al. Indications and results of liver transplantation for Echinococcus alveolar infection: an overview. *Langenbecks Arch Surg* 2003; **388**:231–8.
- Nunnari G, Pinzone MR, Gruttadauria S, Celesia BM, Madeddu G, Malaguarnera G, Pavone P, Cappellani A, Cacopardo B. Hepatic echinococcosis: Clinical and therapeutic aspects. *World J Gastroenterol* 2012 Apr 7; **18**(13):1448–58, 10.3748/wjg.v18.i13.1448.
- Sakçak I, Eriş C, Ölmez A, Kayaalp C, Yilmaz S. Replacement of the vena cava with aortic graft for living donor liver transplantation in Budd-Chiari syndrome associated with hydatid cyst surgery: a case report. *Transplant Proc* 2012; **44**(6):1757–8.
- Hatipoglu S, Bulbuloglu B, Piskin T, Kayaalp C, Yilmaz S. Living donor liver transplantation for alveolar echinococcosis is a difficult procedure. *Transplant Proc* 2013 Apr.; **45**(3):1028–30.
- Buttenschoen K, Carli Buttenschoen D, Gruener B, Kern P, Beger HG, Henne-Bruns D, et al. Long-term experience on surgical treatment of alveolar echinococcosis. *Langenbecks Arch Surg* 2009; **394**(4):689–98, <http://dx.doi.org/10.1007/s00423-008-5>.
- Haberal M, Dalgic A. New concepts in organ transplantation. *Transplant Proc* 2004; **36**:1219.
- Koch S, Bresson-Hadni S, Miguet JP, Crumbach JP, Gillet M, Manton GA, et al. Experience of liver transplantation for incurable alveolarchinococcosis: a 45-case European collaborative report. *Transplantation* 2003; **75**:856.
- Xia D, Yan LN, Li B, Zeng Y, Cheng NS, Wen TF, et al. Orthotopic liver transplantation for incurable alveolar echinococcosis: report of five cases from west China. *Transplant Proc* 2005; **37**:2181.
- Matsuda H, Sadamori H, Shinoura S, Umeda Y, Yoshida R, Satoh D, et al. Aggressive combined resection of hepatic inferior vena cava, with replacement by a ringed expanded polytetrafluoroethylene graft, in living-donor liver transplantation for hepatocellular carcinoma beyond the Milan criteria. *J Hepatobiliary Pancreat Sci* 2010 Sep.; **17**(5):719–24, <http://dx.doi.org/10.1007/s00534-010-0287-z>.
- Ueda J, Yoshida H, Mamada Y, Taniai N, Yoshioka M, Kawano Y, et al. Surgical resection of a leiomyosarcoma of the inferior vena cava mimicking hepatic tumor. *Case Rep Med* 2013; **2013**:235698, <http://dx.doi.org/10.1155/2013/235698>.

#### Open Access

This article is published Open Access at [sciedirect.com](http://sciedirect.com). It is distributed under the [IJSCR Supplemental terms and conditions](#), which permits unrestricted non commercial use, distribution, and reproduction in any medium, provided the original authors and source are credited.